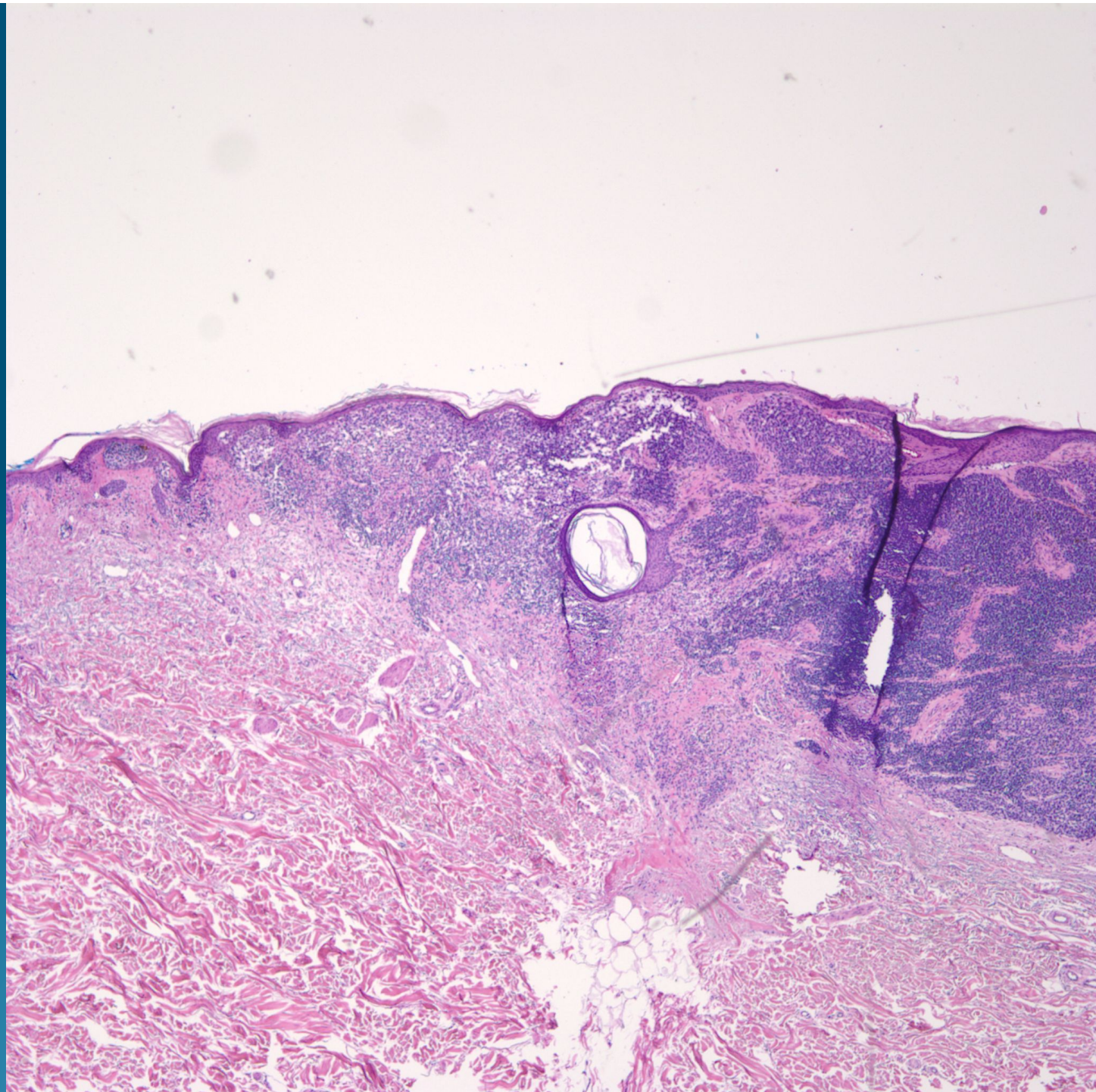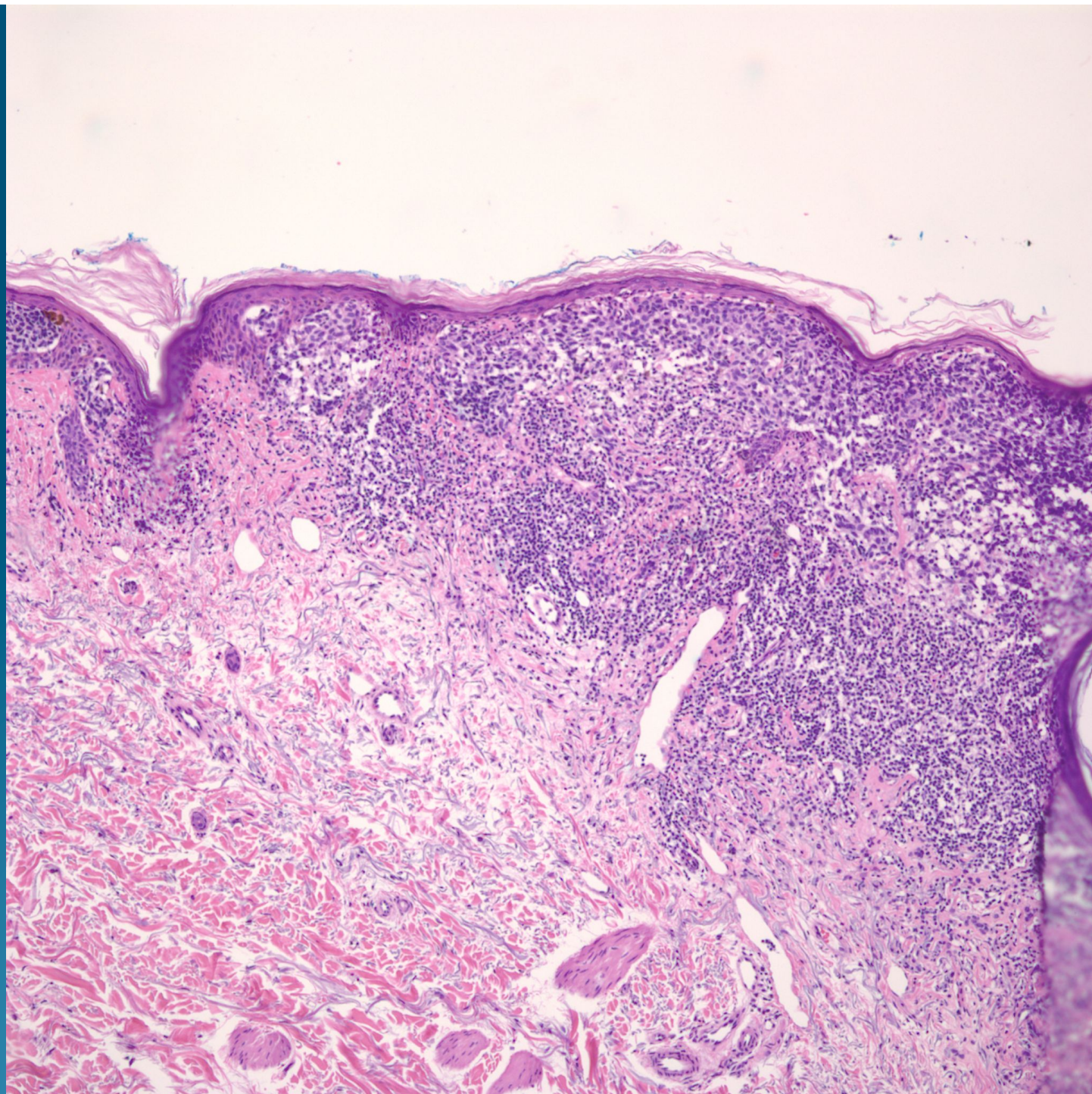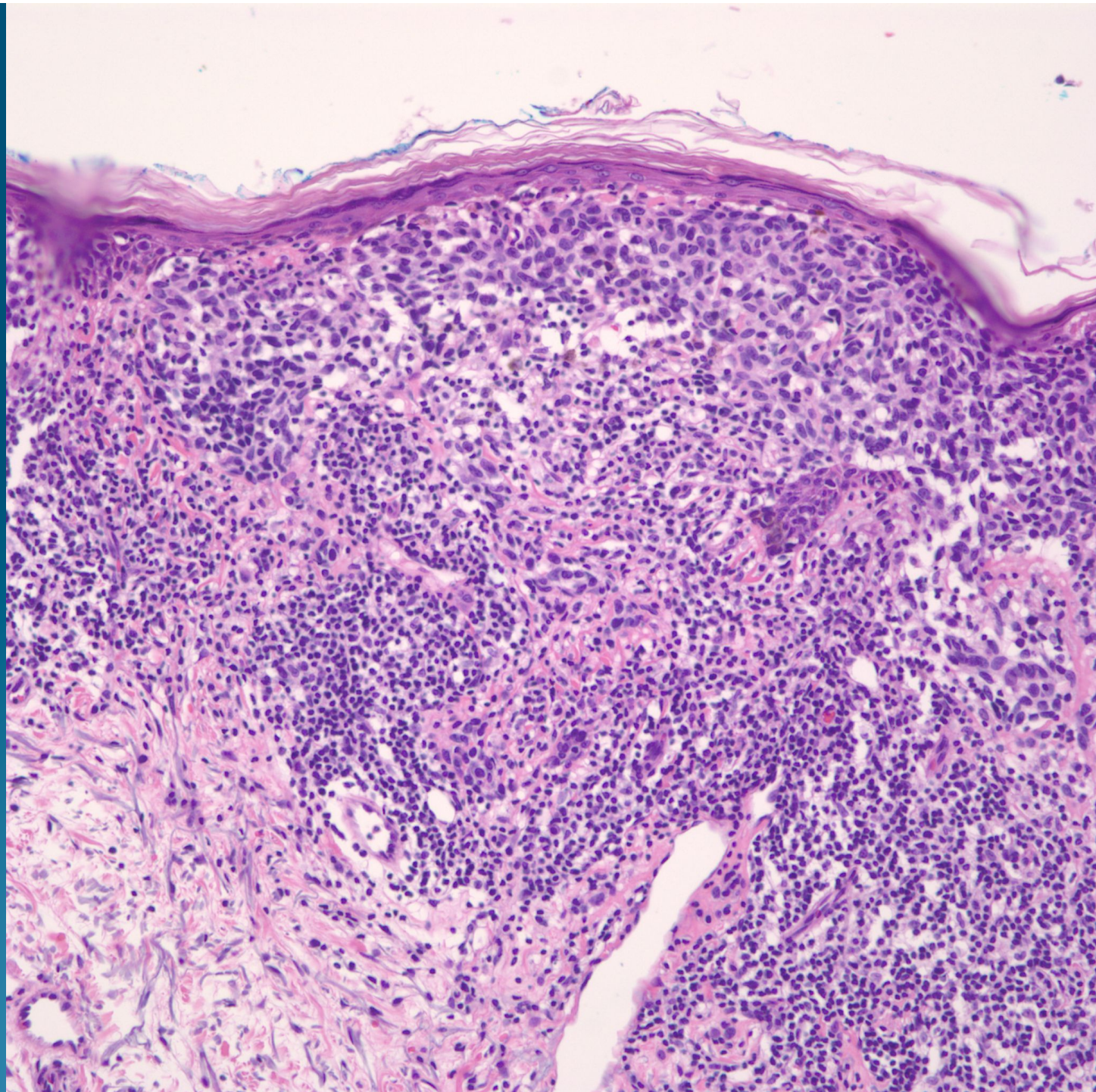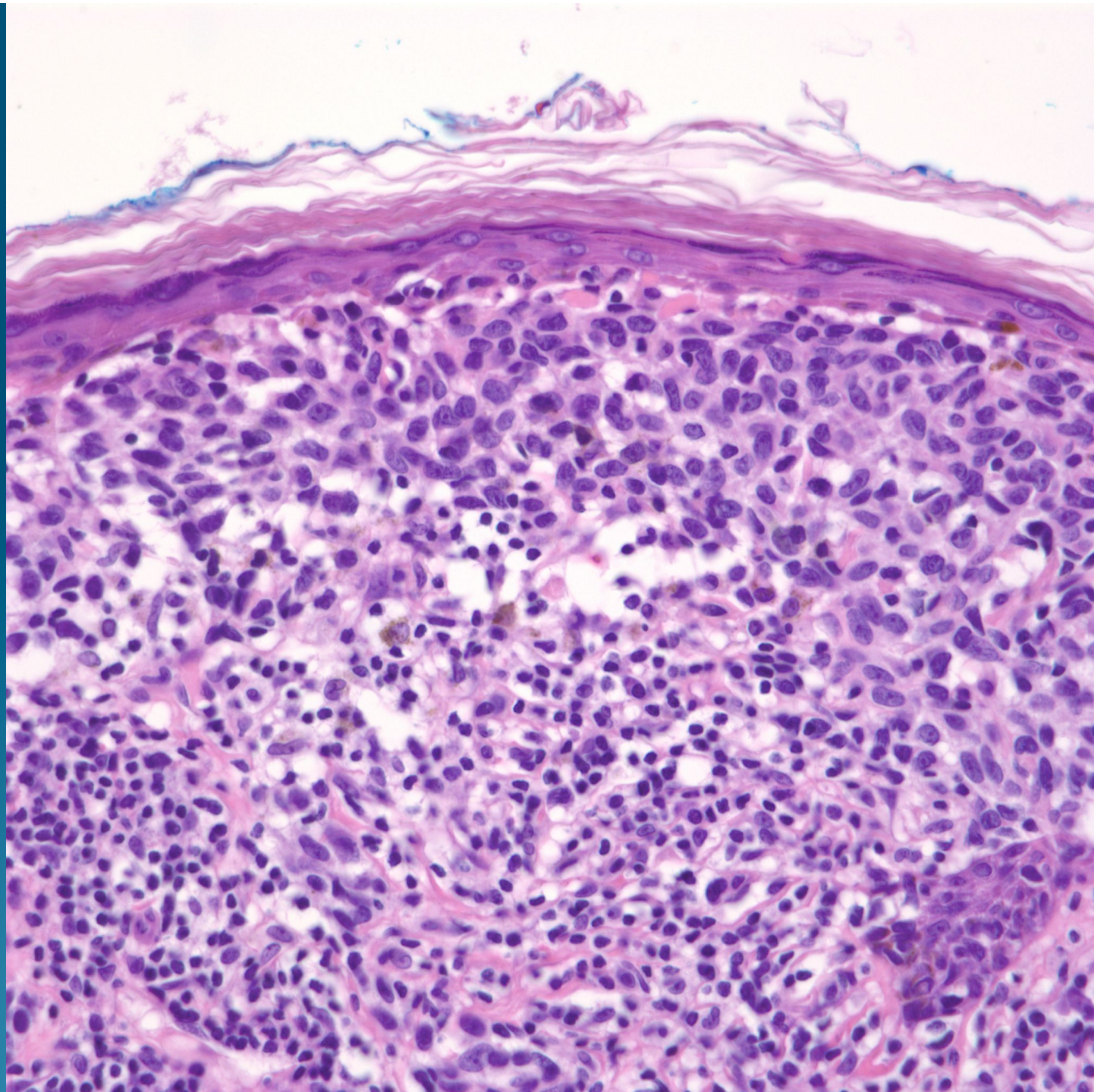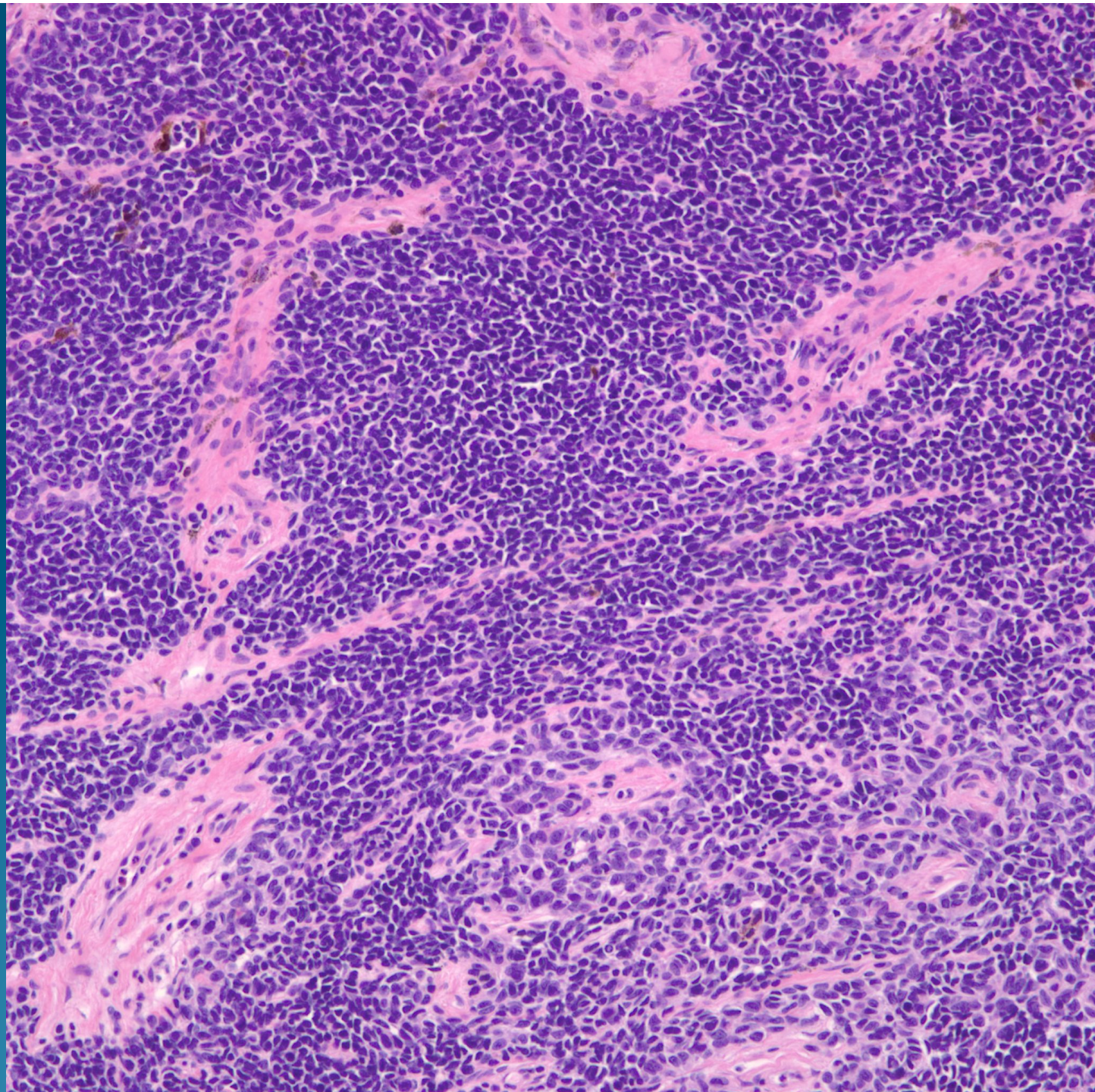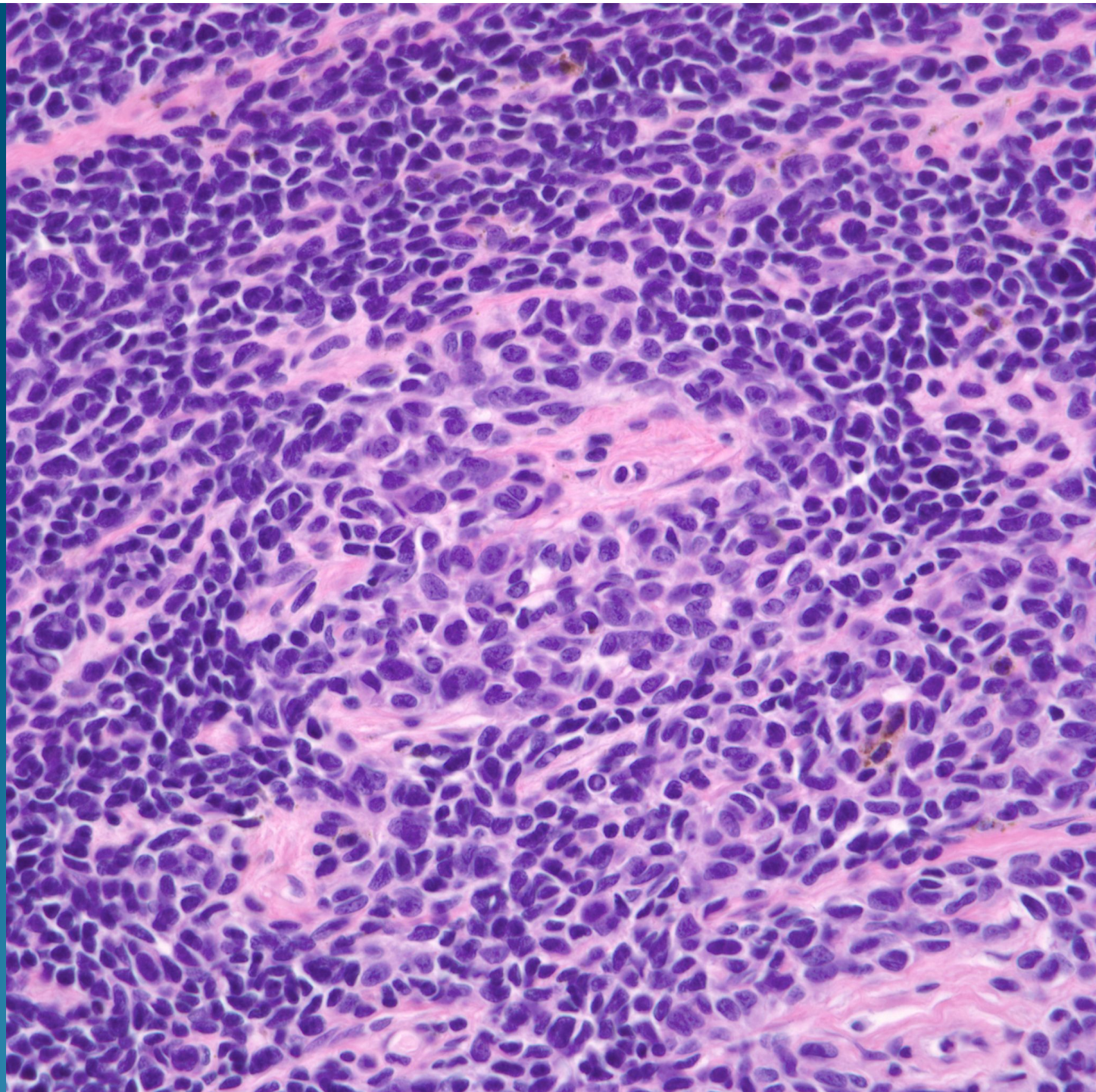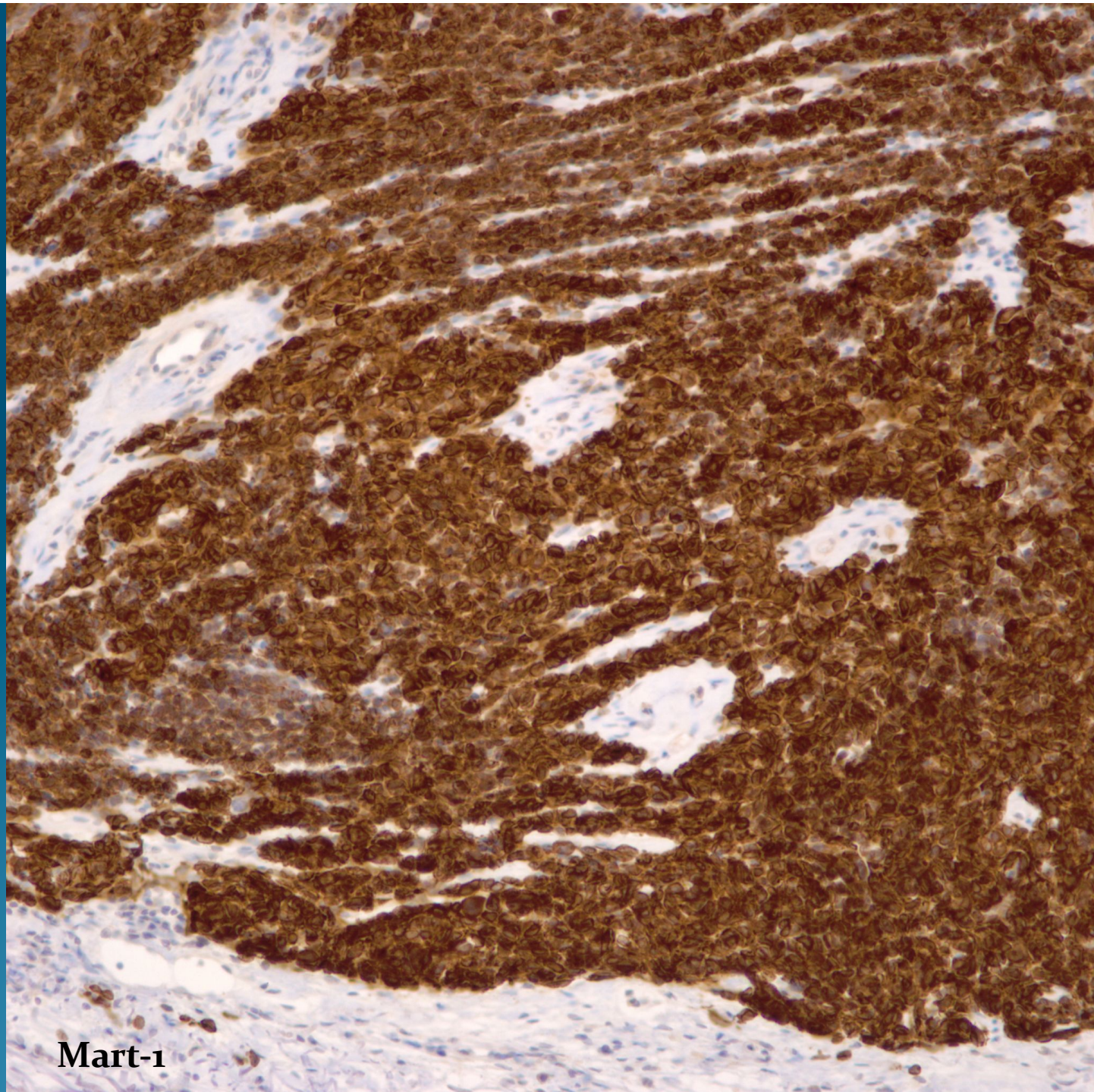


What is the best diagnosis?

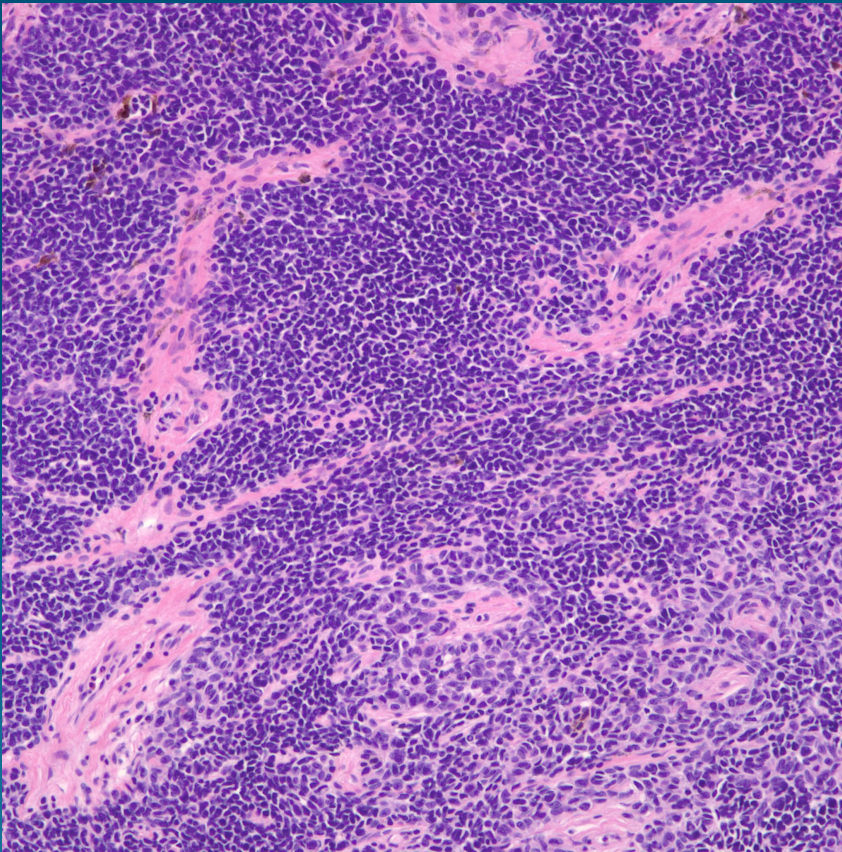
- A. Malignant melanoma
- B. Merkel cell carcinoma
- C. Poorly differentiated squamous cell carcinoma
- D. Nodular basal cell carcinoma
- E. Metastatic renal cell carcinoma

Malignant Melanoma



Mart-1

Pearls



- Asymmetric proliferation of pleomorphic melanocytes with focal junctional activity
- Look for cytoplasmic melanin pigment, loss of maturation, and mitotic figures
- Variable histopathology including areas of amelanotic melanoma, may need confirmation with melanoma specific antibodies